

Helpful information for evaluation of new neurological symptoms in patients receiving TYSABRI

This information is provided as an education resource for healthcare providers and should be considered current as of the date listed herein. It is not intended to be a substitute for consultation and review of reference materials and medical literature pertaining to individual clinical circumstances. Healthcare providers should make all treatment decisions based on the context of the situation and their own clinical judgment.

Please see the Prescribing Information,
including **BOXED WARNING**, for more information



Background information

JCV infections: Progressive multifocal leukoencephalopathy (PML) and JC virus granule cell neuronopathy (JCV GCN)

1 PML

PML is a demyelinating disease that attacks the central nervous system (CNS). It is caused by a polyomavirus called the JC virus (JCV), which is common and widespread in humans. JCV usually remains latent, typically causing PML only in the setting of immunodeficiency.

The clinical picture of PML or other neurological conditions can be difficult to distinguish from multiple sclerosis (MS), especially early in the disease course. Therefore, this information is intended to offer an overview of some of the key issues regarding the definitive diagnosis of PML, especially as they relate to treatment with TYSABRI. These include:

- Patient monitoring and management
 - Obtaining a pretreatment MRI
 - Performing regular follow-ups
 - Treatment of relapses or other neurological symptoms
- Evaluation of new neurological symptoms in patients receiving TYSABRI
 - Distinguishing PML from MS
 - Suggested diagnostic algorithm
 - Action steps if PML is suspected, including MRI assessment, JCV testing, and plasma exchange (PLEX)
 - Immune Reconstitution Inflammatory Syndrome (IRIS)

2 JCV GCN

JC virus infection of granule cell neurons in the cerebellum (i.e., JCV GCN) has been reported in patients treated with TYSABRI. JCV GCN can occur with or without concomitant PML. JCV GCN can cause cerebellar dysfunction (e.g., ataxia, incoordination, apraxia, visual disorders), and neuroimaging can show cerebellar atrophy. For diagnosis of JCV GCN, an evaluation that includes a gadolinium-enhanced MRI scan of the brain and, when indicated, cerebrospinal fluid analysis for JC viral DNA, is recommended. JCV GCN should be managed similarly to PML.

Adapted from Kappos L et al. *Lancet Neurol.* 2007;6(5):431-441.

Please see the Prescribing Information, including **BOXED WARNING**, for more information

Patient monitoring and management

Management of patients receiving TYSABRI

Pretreatment MRI

Obtaining a pretreatment brain MRI scan is recommended. It may assist in determining whether MRI lesions noted at the time of new neurological signs or symptoms were preexistent. This may assist in the differential diagnosis between PML and MS activity.

Regular follow-ups

All patients treated with TYSABRI should have regular clinical follow-ups to allow for early detection of changes in neurological status. To that end, Biogen, in conjunction with the Food and Drug Administration (FDA), developed a risk management plan for the United States called the TOUCH® Prescribing Program. As part of the TOUCH Prescribing Program:

- Physicians evaluate patients 3 months after the first infusion, 6 months after the first infusion, every 6 months thereafter to determine whether patients should continue on treatment, and for at least 6 months after discontinuing TYSABRI
- Physicians submit the TYSABRI Patient Status Report and Reauthorization Questionnaire to Biogen 6 months after initiating treatment and every 6 months thereafter, ensuring additional monitoring and reporting by Biogen
- Infusion sites administer the Pre-Infusion Patient Checklist and report to the prescriber any changes in the patient's status prior to infusing
 - Infusion sites will not infuse TYSABRI if the patient reports a change in symptoms, unless the prescriber authorizes the infusion

Patient history

Knowing the history and pattern of prior and ongoing MS signs and symptoms can help in the management of patients treated with TYSABRI.

Please see the Prescribing Information, including **BOXED WARNING**, for more information



Evaluation of new neurological symptoms in patients receiving TYSABRI

- If new neurological symptoms develop, withhold TYSABRI dosing and evaluate the patient

Distinguishing PML from MS

The following information should be considered when undertaking the assessment and management of new or worsening neurological symptoms in MS patients treated with TYSABRI. There are no pathognomonic signs or symptoms that distinguish an MS relapse from PML, but there are certain clinical features that may help differentiate between the 2 conditions (see Table 1).

Table 1. Clinical signs and symptoms typical of MS relapse and PML

	MS relapse	PML
ONSET	Acute	Subacute
EVOLUTION	<ul style="list-style-type: none"> • Over hours to days • Normally stabilize • Resolve spontaneously or with treatment 	<ul style="list-style-type: none"> • Days to weeks • Progressive
CLINICAL PRESENTATION	<ul style="list-style-type: none"> • Diplopia • Paresthesia • Paraparesis • Optic neuritis • Myelopathy 	<ul style="list-style-type: none"> • Cortical symptoms/signs • Behavioral and neuropsychological alteration • Retrochiasmal visual deficits • Seizures • Hemiparesis

Not intended to be inclusive of all clinical signs and symptoms indicative of MS and PML.

Please see the Prescribing Information, including **BOXED WARNING**, for more information

Treatment of MS relapse

- Relapses should be managed according to usual clinical practice

If treating with corticosteroids:

- A single short course of corticosteroids can be considered for cases in which PML is unlikely on clinical grounds
- Progression of symptoms, despite treatment with corticosteroids, should trigger further investigation

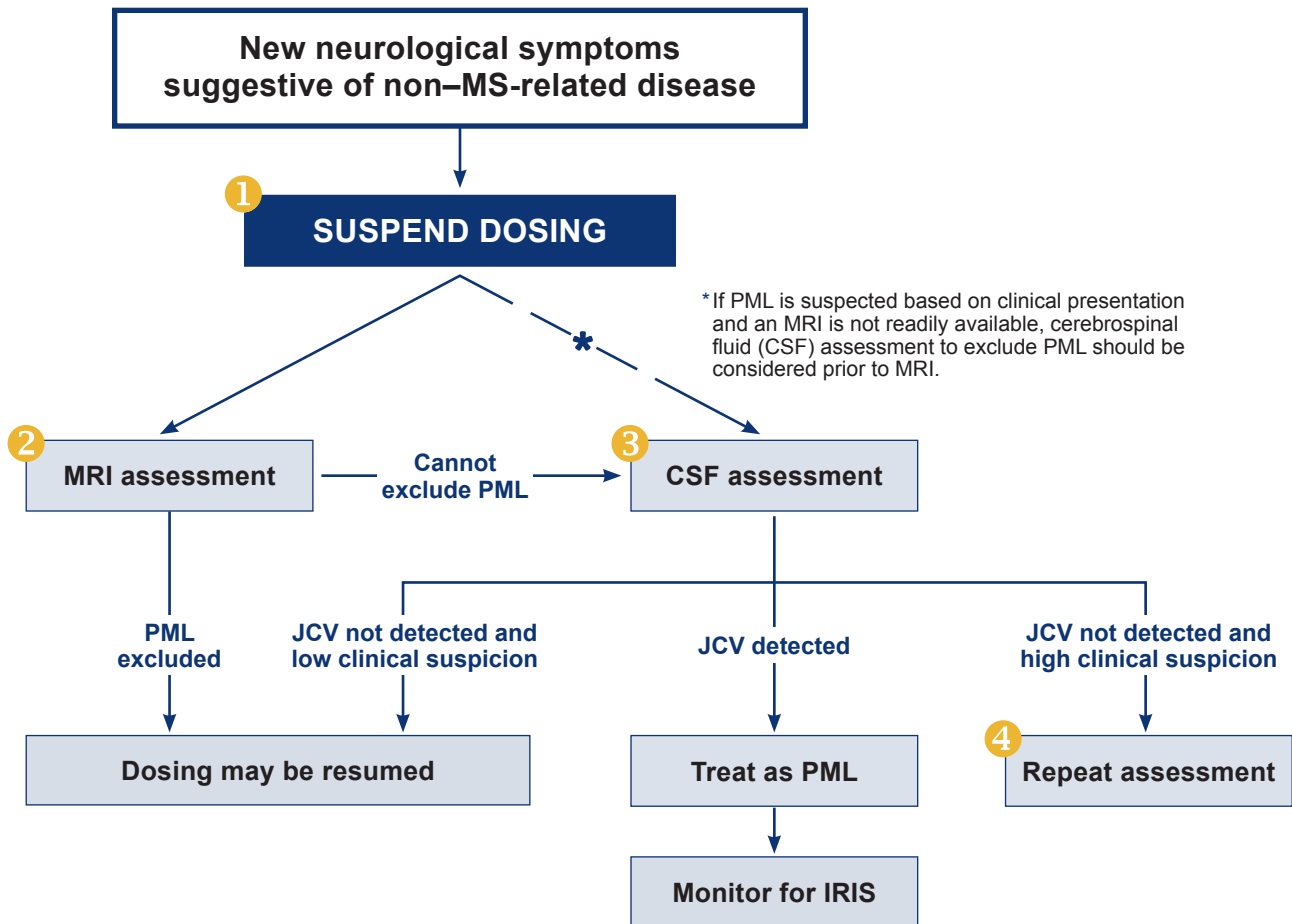
- In addition to PML and MS, other medical and CNS conditions including other infections should be considered when evaluating a patient with new neurological symptoms

New or recurrent neurological symptoms should prompt careful evaluation.

Please see the Prescribing Information, including **BOXED WARNING**, for more information

**TYSABRI**[®]
(natalizumab)

Suggested diagnostic algorithm for TYSABRI-treated patients experiencing new neurological symptoms suggestive of non-MS-related disease



Note: TYSABRI dosing should only be restarted when the diagnosis of PML is excluded, if necessary, by repeating clinical, MRI, and CSF assessment if clinical suspicion of PML remains.

CSF assessment for presence of JCV DNA should be performed using a highly sensitive quantitative real-time PCR assay with a limit of quantification (LOQ) of at least 50 copies/mL.

For more information, please call Biogen Medical Information at 1-800-456-2255.

Please see the Prescribing Information, including **BOXED WARNING**, for more information

Action steps if PML is suspected

1 SUSPEND DOSING

TYSABRI dosing should be suspended **immediately** in all cases in which PML is suspected.

2 MRI assessment

If the clinical presentation is suggestive of PML, further investigation should include brain MRI evaluation as soon as possible.

3 CSF assessment

If MRI evaluation reveals lesions suspicious for PML (see [Table 2 on page 9](#)), a lumbar puncture with evaluation of CSF for the detection of JCV DNA should be undertaken with a highly sensitive quantitative real-time PCR assay.

4 Repeat testing

If clinical suspicion of PML remains despite a negative evaluation, then MRI and CSF assessments should be repeated to exclude a diagnosis of PML.

A definitive diagnosis of PML is made by evaluating clinical and MRI findings plus the identification of JCV in the CNS.

- There is no prevention, FDA-approved treatment, or cure for PML. Rapid recognition of PML and early discontinuation of TYSABRI are key interventions
- PLEX (see [page 10](#)) may be considered as a means to accelerate the clearance of TYSABRI
- Healthcare providers should promptly report serious adverse events to Biogen at **1-800-456-2255** — Biogen can provide additional resources, including suggested next steps

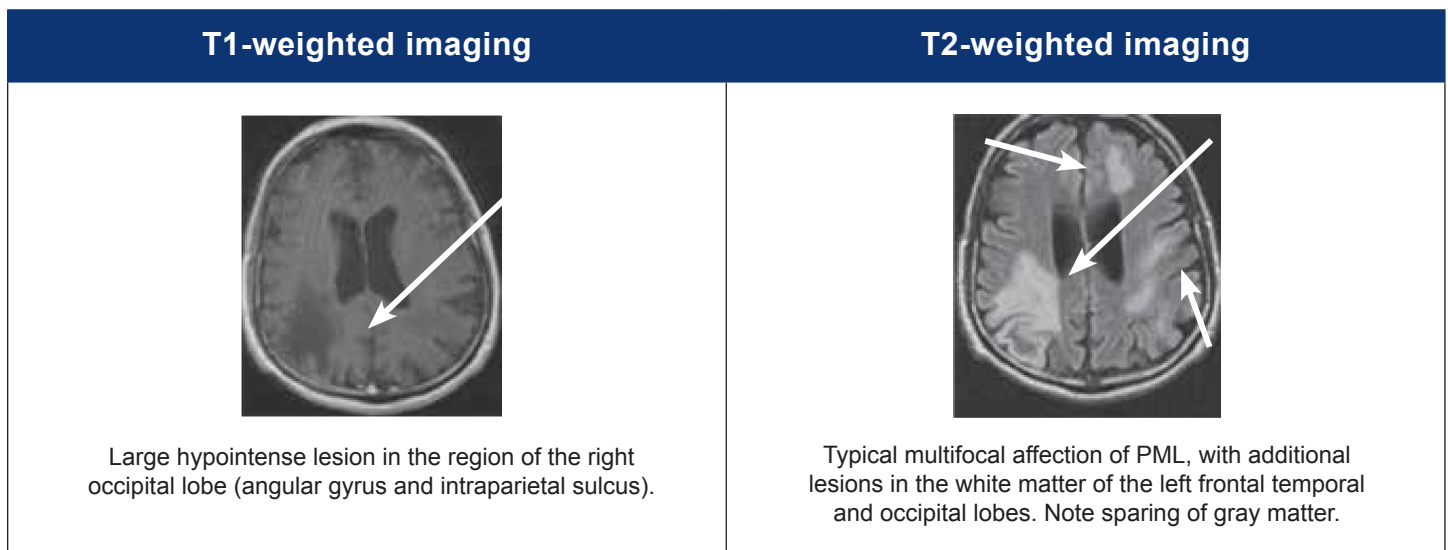
Please see the Prescribing Information, including **BOXED WARNING**, for more information


TYSABRI[®]
(natalizumab)

MRI assessment

- Although there are no pathognomonic findings that differentiate PML from MS, a brain MRI scan that includes fluid-attenuated inversion recovery (FLAIR) and T1- and T2-weighted sequences, with and without gadolinium (Gd), should be performed to assess patients with neurological changes suggestive of PML (see [Table 1](#) on page 4)
- Comparison with a baseline scan may assist with interpretation of the findings on the new MRI. See [Figure 1](#) and [Table 2](#) for differences in lesion characteristics that may help differentiate between PML and MS

Figure 1. MRI presentation features of PML



Adapted from Weber T. *Neurol Clin.* 2008;26(3):833-854. Used with permission.

Please see the Prescribing Information, including **BOXED WARNING**, for more information

Table 2. MRI lesion characteristics typical of PML and MS

Characteristic	MS Lesions	PML Lesions
Location	Periventricular perpendicular to ventricles (Dawson’s fingers), deep white matter, isolated U fibers, cerebellum, and spinal cord	<ul style="list-style-type: none"> • Subcortical WM in parietal, occipital, or frontal lobes • May involve precentral or postcentral gyrus (motor/sensory cortex) or insular region • Follows WM tracks. Can cross the corpus callosum to contralateral hemisphere (butterfly pattern) or extend through internal capsule • Rarely brainstem or cerebellar WM • No spinal cord involvement
Appearance	Well-defined borders	<ul style="list-style-type: none"> • Infiltrating, ill-defined, confluent WM lesions, which can be multifocal
Mass effect	Large lesions can have a mass effect	<ul style="list-style-type: none"> • Rare even in large lesions
FLAIR	Flair = T2	<ul style="list-style-type: none"> • Flair more sensitive for detection of PML lesions in subcortical location
T1W pre-contrast	Isointense or mildly hypointense to grey matter	<ul style="list-style-type: none"> • Isointense with progressive hypointensity
T1 post contrast	Homogeneous or ring-enhancement—resolves in 1-2 months	<ul style="list-style-type: none"> • Patchy, punctate, or linear

Adapted from Yousry TA et al. *N Eng J Med.* 2006;354(9):924-933.

Please see the Prescribing Information, including **BOXED WARNING**, for more information



JCV DNA testing to confirm diagnosis

- Plasma assessment
 - Presence of JCV DNA in plasma has not been correlated with the development of PML
 - Plasma JCV DNA test positivity is highly variable, so the sensitivity and predictive value of this screening method are unclear
 - Plasma JCV DNA testing is not included in the TOUCH Prescribing Program
- CSF assessment
 - The detection of JCV DNA in the CSF of a patient with clinical and MRI features suggestive of PML establishes the diagnosis of PML
 - If clinical suspicion of PML remains despite a negative CSF, testing should be repeated
 - It is recommended to test samples using a validated ultrasensitive quantitative PCR test that has a lower limit of quantification of 50 copies per mL or lower
- Brain biopsy
 - If diagnosis remains uncertain and suspicion of PML remains high, a brain biopsy may be considered to establish a definitive diagnosis

Note: TYSABRI dosing should only be resumed if the diagnosis of PML is excluded and if deemed appropriate for the ongoing treatment of MS.

PLEX

- Three sessions of plasma exchange (PLEX) over 5 to 8 days were shown to accelerate TYSABRI clearance in a study of 12 patients with MS who did not have PML, although in the majority of patients, α 4-integrin receptor binding remained high—a potential sign of continued inhibition of α 4-integrin-mediated leukocyte activity
- Additional plasma exchanges (up to a total of 5 over a 10-day period) may more consistently reduce TYSABRI plasma concentration and α 4-integrin receptor binding to below subtherapeutic levels
- Adverse events that may occur during PLEX include clearance of other medications and volume shifts, which have the potential to lead to hypotension or pulmonary edema
- Although PLEX has not been prospectively studied in TYSABRI-treated patients with PML, it has been used in such patients in the postmarketing setting to remove TYSABRI more quickly from the circulation
- There is no evidence that PLEX has any benefit in the treatment of opportunistic infections such as PML
- Physicians should use medical judgment when considering the use of PLEX to treat PML

Adapted from Khatri BO et al. *Neurology*. 2009;72(5):402-409.

Please see the Prescribing Information, including **BOXED WARNING**, for more information

Immune Reconstitution Inflammatory Syndrome (IRIS)

- IRIS has been reported in the majority of patients who developed PML and subsequently discontinued TYSABRI
- In almost all cases, IRIS occurred within days to several weeks after plasma exchange was used to accelerate TYSABRI clearance
- IRIS usually presents as an unanticipated clinical decline, which may be rapid and severe, and may be fatal
- At the time of IRIS, MRI may show additional changes including Gd enhancement
- Monitoring for development of IRIS and appropriate treatment of the associated inflammation should be undertaken

For the latest scientific information about our products or to report an adverse event, contact:

Biogen Medical Information

Telephone: 1-800-456-2255 (8:30 AM to 8:00 PM ET)

Fax: Send Medical Information Request Form to
1-877-462-1530

Web: <http://medinfo.biogen.com>

E-mail: medinfo@biogen.com

To report an adverse event, contact:

Biogen

Telephone: 1-800-456-2255

Please see the Prescribing Information, including **BOXED WARNING**, for more information



Please see the Prescribing Information,
including **BOXED WARNING**, for more information



© 2006-2023 Biogen

04/2023

TYS-US-0480 V6

